

Oedema

(Fluid retention)

in Prader-Willi Syndrome*

Linda M. Gourash, MD

Pittsburgh Partnership

Clinical Advisory Board, PWSA-USA

Dr. Gourash is a Pediatrician who has worked extensively rehabilitating hospitalized patients with PWS.

Fluid retention is usually noted first as swelling of the lower legs. In PWS this is a valuable warning sign that poor weight control is affecting the person's health. Fluid retention in persons with PWS is usually a sign of a decreased ability to breathe adequately due to excessive weight ("obesity hypoventilation"). With excessive weight, breathing abnormalities first develop during sleep and can be present silently for years without any other signs that something is amiss.

Although oedema often is the earliest clinical sign of obesity-hypoventilation; *it is frequently missed*. The reason for this appears to be the visual subtlety of oedema in both the obese child and obese adult. One useful way to describe this type of oedema is by feel: the fat "gets hard" as the turgor (firmness) of the lower legs or (usually later) the abdomen increases. Tactile *comparison* of tissue in the lower part of the body with the upper extremities will help to demonstrate an increased density of the tissue in the lower part of the body. The level of the firmer tissue is usually well demarcated to the knees, thighs, hips, waist, or higher. This finding is less appreciable in children who can nevertheless be quite compromised by fluid retention and poor ventilation. In the absence of diuretic use, the level of oedema correlates fairly well with the severity of the nocturnal hypoxia (low oxygen). Therefore detection of a lesser degree of oedema to the knees or thighs is especially valuable as an early sign of cardiopulmonary compromise. These patients typically have normal resting oxygen saturations during the day but pulse oximetry testing during exercise will sometimes demonstrate desaturation. In the presence of *any* recognizable oedema, nocturnal oxygen abnormalities (levels below 92%) are usually quite extensive and may be present throughout the night without the arousal from sleep usually noted with sleep apnea.

Decreased exercise tolerance can also be a sign of obesity hypoventilation.

However, decreased tolerance is difficult to differentiate from the noncompliance with exercise often displayed by persons with the syndrome. Families do not always perceive the symptom because young children are adept at appearing to carry out their usual activities while conserving their energy. Similarly, orthopnea (sleeping with extra pillows or sitting up) and symptoms of OSA (obstructive sleep apnea) are only sometimes present.

Rapid weight gain in an individual with PWS that is not explained by increased access to food may also be the first sign of fluid retention.

Complications:

Longstanding oedema results in chronic tissue changes of the lower body including legs and lower abdomen. The resulting venous stasis and lymphatic damage predispose tissue to ulcers, thrombosis, and cellulitis (tissue infection.) Intervention to ameliorate the underlying condition of obesity hypoventilation is essential to avoid irreversible damage to the lymphatic and venous systems of the lower legs. There is no question that skin-picking behavior in those with PWS, while not usually resulting in infection in other parts of the body, is a major contributor to some episodes of leg cellulitis.

Infection (Cellulitis) of the oedematous tissue

Signs of cellulitis can be difficult to ascertain in the very obese individual since the legs are often already chronically swollen, indurated (skin thickened and hard) and discolored even without infection. A high index of suspicion and close daily

Notes for Physicians

1. *Pitting is usually absent* even in the presence of massive oedema
2. *Abnormalities on chest radiograph (X-ray picture) and even echocardiography* are a very late finding long after the individual is quite compromised.
3. End stage obesity hypoventilation includes right heart failure from pulmonary hypertension and, far less often, some left ventricular dysfunction. For this reason, despite massive tissue oedema, pulmonary oedema is not typically part of the clinical picture. Increased activity is more effective and safer than diuretics.
4. Cellulitis: Abnormalities in white blood cell count, fever, pain or measurements of inflammatory markers can be delayed or minimal even with serious infections. Oral antibiotics, sometimes in combination with an antifungal agent (such as fluconazole) are usually effective.

examination of the legs by caretakers seeking changes in feel or appearance is essential. Patients do not always exhibit fever or pain. Limited cases of cellulitis, diagnosed early, can be managed with oral antibiotics. Preventative use of antibiotics is discouraged to prevent development of resistant strains of bacteria. However, intravenous antibiotic may be necessary in severe cases, especially if there is evidence of systemic infection (fever or malaise). In all cases, an attempt should be made to identify the causative organism but this is not always possible.

Maintaining and increasing physical activity and leg elevation when the patient is sitting have proven useful adjuncts in the management of these difficult conditions. Cellulitis and superficial venous thrombosis are not reasons to limit activity; rather, the reverse is true. Patients who have ceased to walk for any reason are at high risk for thromboembolic events (blood clots) and prophylactic anticoagulation should be considered.

Management of Oedema:

Direct pressure techniques to the legs or use of support hose appear to be of very limited usefulness unless they are part of a full medical protocol for treatment of lymphoedema. In some cases, support stockings may be counterproductive, causing tissue breakdown from pressure or constriction of fluid outflow.

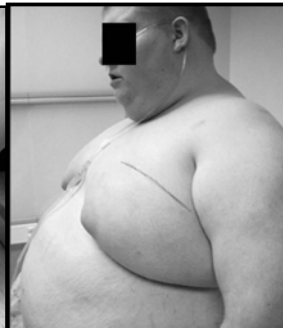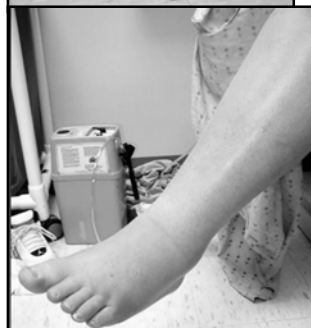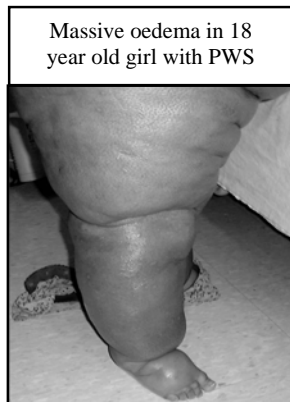
Rehabilitation to some level of ambulation is the highest priority. Ambulation without the use of diuretics is very effective in mobilizing fluid and causing a natural diuresis. This means that fluid previously contained in the tissue is moved back into the veins (by the action of the muscles contracting), returned to the heart and eliminated by the kidneys. Sometimes within days of increased activity there is evidence of increased urination and a rapid loss of weight can be documented by daily weight checks. This weight loss can be impressive (up to 4 pounds (2 kg) per day) in massively oedematous persons. Losses of .5 kg/day are more typical; this effect can be delayed for weeks in patients who are more ill.

Besides mobilizing the fluid, increased physical activity alone can greatly reduce and even eliminate the low oxygen and even the obstructive sleep apnea causing the oedema. At times it may be prudent to treat these conditions independently with CPAP or BiPAP but this is frequently not necessary if the individual can embark successfully on a program of increased daily activity.

Oxygen use especially *without* the assisted ventilation of CPAP or BiPAP is risky as persons with PWS may lose their drive to breath when they are given oxygen and die of CO₂ retention. This is usually a subtle change of worsening hypoventilation that develops over hours or days. *Overuse of oxygen and of diuretics are the 2 most dangerous and common errors of rehabilitating persons with obesity hypo-ventilation and oedema.*

Even persons who are very compromised from their obesity and low oxygen levels must begin to move even if it is only a few more steps per day than previously attempted. Using a walker is very helpful for the sick patient who has been very sedentary.

Using lots of encouragement and incentives, persons with PWS can be induced to walk more each day with a goal of 1 hour per day (in 2 shorter sessions). They will virtually always experience a great improvement in their oedema. If the leg swelling has been present for years some swelling of the lower legs will often remain due to the damage to the veins and lymphatics. Therefore early intervention is ideal.



(Left) Despite only subtle changes in legs, this 19 year old man had oedema to the chest. (Right) Two older individuals with chronic changes from long standing oedema

